



PATIENT

Jingle Dussault

SPECIES

Feline

BREED

Maine Coon

SEX

Male Neutered

AGE

5.6 years

WEIGHT

16.68lbs

INTERPRETED BY

Maggie Machen
Lamy, DVM
DACVIM (Cardiology)

IMAGING

PERFORMED BY

Pamela Harrigan,
RDCS

HOSPITAL NAME

Anchor Animal
Hospital

REFERRING VET

Dr. Pietsch

INVOICE

31688

DATE

7/6/23

PRESENTING CLINICAL SIGNS

History: Patient has a history of an intermittent grade II/VI systolic murmur. Heart is mildly enlarged, and valentine shaped on z-rays. No symptoms of CHF. ProBNP 67. BP: 115-125mmHg. Sedated with torb/alfaxan

ECHOCARDIOGRAM FINDINGS

2D, m-mode, color flow and Doppler imaging is available.

Left ventricle: The LV diameter is normal with adequate myocardial function. The LV wall thicknesses are largely normal. There is a mildly hyperechoic endocardium consistent with mild fibrosis. The endocardium appears mildly remodeled. The papillary muscles are mildly remodeled and hyperechoic.

Left atrium: The left atrium is normal in dimension for this signalment. No obvious spontaneous contrast or thrombi seen.

Mitral valve: The mitral valve is normal in structure and mobility. No obvious systolic anterior motion is seen. Trivial MR.

Aortic valve/aorta: The aortic valve is normal in morphology and mobility. Normal aortic outflow velocity; laminar flow. No aortic insufficiency.

Right ventricle: Normal right ventricular diameter and morphology indicating no overt evidence of pulmonary arterial hypertension.

Right atrium: The right atrium is normal in dimension.

Tricuspid valve: The tricuspid valve appears normal with mild tricuspid regurgitation. Normal velocity.

Pulmonic valve/pulmonary artery: The pulmonic valve is normal in morphology and mobility. No pulmonic insufficiency. Normal RVOT velocity; laminar flow.

Pericardium/other: No pericardial or pleural effusion noted. No obvious cardiac masses.

Heart rhythm: ECG reveals a sinus rhythm with an average HR of 120bpm.

2-Dimensional Measurements

Ao diam (cm)	1.2
LA diam (cm)	1.4
LA:Ao (Swe)	1.2
IVS thickness (cm)	0.50
LVID diastole (cm)	1.6
PW thickness (cm)	0.50
LVID systole (cm)	0.8
FS (%)	50

Doppler Measurements

PV Vmax (m/s)	0.8
AoV Vmax (m/s)	1.0
MR Vmax (m/s)	NA
TR Vmax (m/s)	1.8
TR PG (mmHg)	13

INTERPRETATION OF THE FINDINGS

Essentially normal cardiac structure and function. The LV wall thickness is normal and there is no evidence of elevated left atrial pressure. There is mild remodeling and fibrosis of the left ventricular wall, which is considered normal. Mild TR is noted, which appears hemodynamically insignificant. It is unclear if this would be heard upon exam. No alternative cause for the murmur is identified in this study, making it likely physiologic in origin (i.e., secondary to tachycardia, volume changes, etc.).

It is important to note that phenotypic HCM can develop at any age, and routine screening is recommended in this predisposed breed.



PATIENT

Jingle Dussault

SPECIES

Feline

BREED

Maine Coon

SEX

Male Neutered

AGE

5.6 years

WEIGHT

16.68lbs

INTERPRETED BY

Maggie Machen Lamy, DVM
 DACVIM (Cardiology)

IMAGING PERFORMED BY

Pamela Harrigan, RDCS

HOSPITAL NAME

Anchor Animal Hospital

REFERRING VET

Dr. Pietsch

INVOICE

31688

DATE

7/6/23

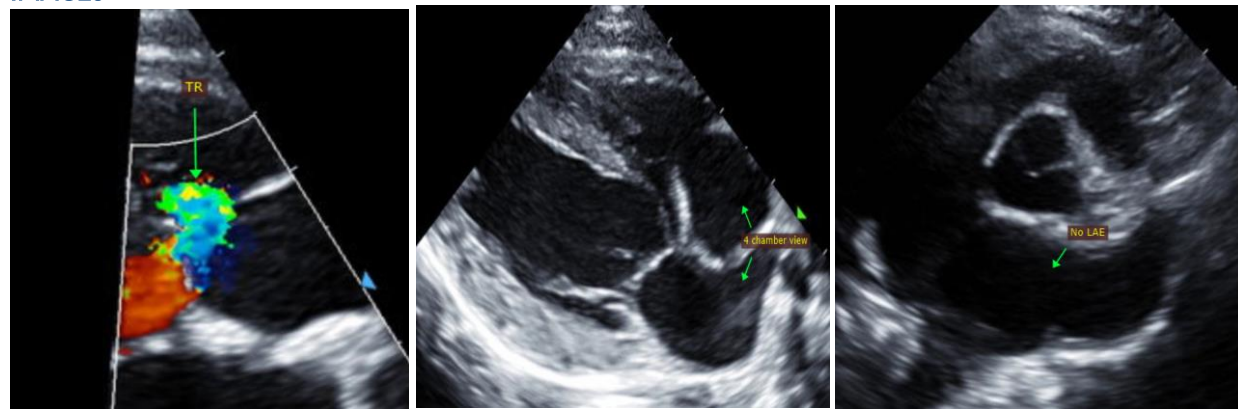
RECOMMENDATIONS

- Given these findings, no medications are indicated.
- No cardiac contraindication for general anesthesia. Mild IV fluid restriction is advised.
- Risk for complication with steroid use typically follows LA dilation, which in this case is low. That being said, any cat can experience unexpected signs of intolerance and monitoring of RR/RE is advised particularly in the initiation phase.
- Monitor for any clinical evidence of cardiac compromise, including respiratory changes and/or signs of a blood clot event (paralysis, neurologic changes, etc.).

PLAN

- Recommend recheck echocardiogram in 1 year to reassess murmur origin and screen for development of disease the pre-existing murmur may mask.

IMAGES



The information and recommendations provided are based on the images presented by the referring veterinarian. No evaluation can be communicated regarding pathology that was not visible in the image/video clips provided.

Thank you for this referral. This report was generated using transcription software, and minor dictation errors may be present. If the clinical or image interpretation does not parallel your findings or if I can be of any further assistance, please contact me.

Maggie Machen Lamy, DVM
 Diplomate of the American College of Veterinary Internal Medicine (Cardiology)
 info@sonopath.com

Echocardiogram performed by: Pamela Harrigan, RDCS
 Pet Animal Ultrasound Service (4paus.com)